

# A Split-Face, Double-Blind, Randomized and Placebo-Controlled Pilot Evaluation of a Novel Oligopeptide for the Treatment of Recalcitrant Melasma

Basil M. Hantash MD PhD<sup>a</sup> and Felipe Jimenez PhD<sup>b</sup>

<sup>a</sup>Elixir Institute of Regenerative Medicine, San Jose, CA

<sup>b</sup>JDerm Consulting, Inc, Seal Beach, CA

## ABSTRACT

Melasma is a cutaneous disorder associated with an overproduction of melanin by the tyrosinase enzyme. A proprietary oligopeptide (Lumixyl™) was previously shown to competitively inhibit mushroom and human tyrosinase without the associated toxicity of hydroquinone. The aim of this split-face, randomized, double-blind and placebo-controlled pilot study was to determine the effect of twice-daily topical application of this oligopeptide (0.01% w/w) on moderate, recalcitrant melasma over a 16-week course. Five female participants with Fitzpatrick phototype IV and moderate recalcitrant melasma enrolled and completed the study. Improvement in melasma and overall facial aesthetics as well as assessment of volunteer satisfaction was measured using 10- and five-point grading scales, respectively. Treatment was well tolerated with no visible signs of irritation or allergy. All five participants demonstrated statistically significant improvement in the appearance of melasma and overall facial aesthetics with high patient satisfaction. Results suggest that the oligopeptide may be useful in the treatment of melasma and warrants further evaluation.

## INTRODUCTION

Melasma is a common cutaneous disorder that presents as patches of darker pigmentation on the cheeks, forehead, upper-lip, nose and chin.<sup>1</sup> Melasma most commonly affects females of Asian and Hispanic descent having Fitzpatrick phototypes IV and higher and only a very small percentage of men.<sup>2</sup> Moreover, pregnancy appears to be a contributing factor in bringing about the onset of melasma in females, supporting the proposed role of hormones in the regulation of melanogenesis in women.<sup>3,4</sup> Various skin lightening agents such as kojic acid, azelaic acid, ascorbic acid (and its derivatives) and hydroquinone (and its arbutin derivatives) are currently used to treat melasma but are either efficacious and cytotoxic or are mildly efficacious and non-toxic.<sup>5</sup> Hence there is a need for novel compounds that strike a balance between skin lightening efficacy and toxicity.

The authors have previously demonstrated that a novel proprietary synthetic oligopeptide (Lumixyl™) competitively inhibits both mushroom and human tyrosinase enzymes better than hydroquinone at similar concentrations.<sup>6</sup> Moreover, cell culture studies with human melanocytes confirmed that the oligopeptide also inhibited intracellular tyrosinase better than hydroquinone without cytotoxicity. Given the superior tyrosinase-inhibiting properties of the oligopeptide over hydroquinone, it was hypothesized that the oligopeptide might be useful for the treatment of melasma. The aim of the present translational pilot study was to determine if twice-daily topical application of

0.01% Lumixyl, in an inert emulsion vehicle, could improve the appearance of recalcitrant melasma after a 16-week course.

## METHODS

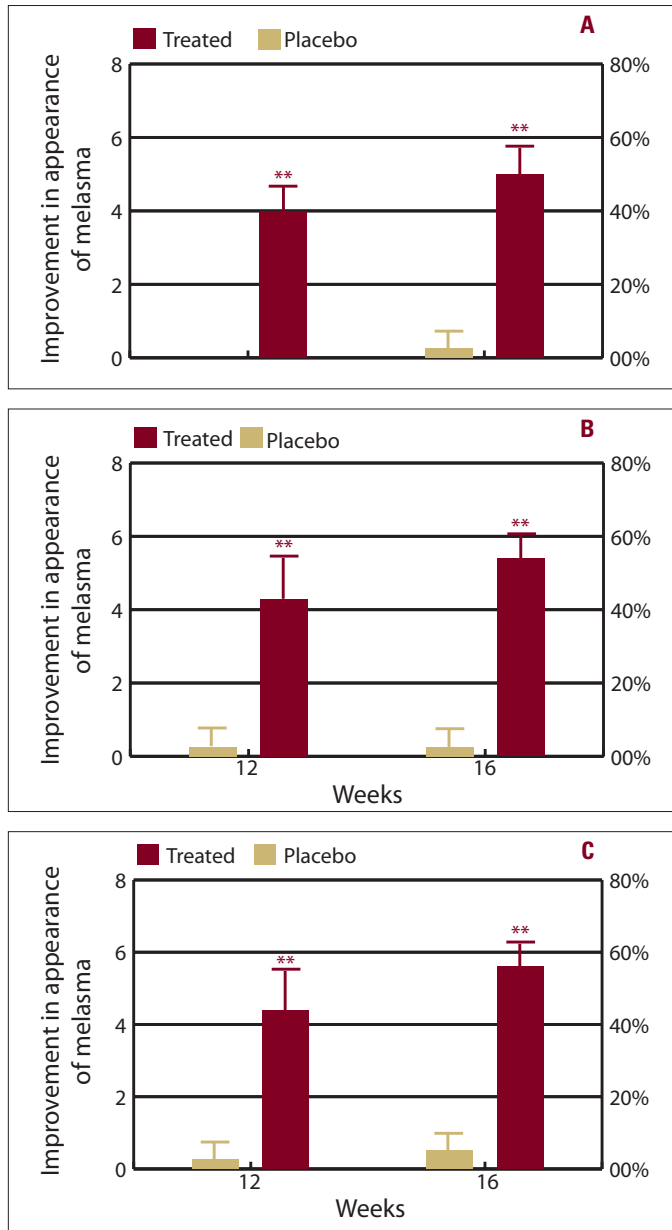
A split-face, double-blind, randomized and placebo-controlled study was conducted to assess the effects of a novel proprietary synthetic oligopeptide (Lumixyl, Emed, Inc., Westlake Village, CA) on the appearance of facial melasma. The secondary objectives were to evaluate the effect of the oligopeptide on the overall facial appearance of study participants and their respective satisfaction with their improvements or lack thereof.

Lumixyl was synthesized via solid-phase Fmoc chemistry and incorporated into an inert oil-in-water emulsion at a concentration of 0.01% (w/w). Both the oligopeptide-containing formula and vehicle alone were tested on all participants in a randomized, split-face fashion. Volunteers were instructed to wash their face with Dove Soap (Procter & Gamble, Cincinnati, OH), dry thoroughly and apply a pea-size amount of oligopeptide-containing formula on one side of the face and vehicle alone on the other side twice-daily for 16 weeks. Compliance with the prescribed treatment regimen was monitored by comparing the weights of the study products at 12 and 16 weeks with baseline weights. This study was approved by the local institutional review board (IRB) and was conducted following the guidelines of the Declaration of Helsinki.

Five healthy female subjects were enrolled in the study. Partici-

pants eligible for inclusion in the study were between the ages of 30 and 45, were of Hispanic or Asian decent and had Fitzpatrick III to IV skin types with moderate-to-severe recalcitrant melasma. Eligible participants had just completed and failed a six-month treatment of twice-daily Tri-Luma® (Galderma, Ft. Worth, TX). Moreover, all subjects demonstrated accentuation

of facial pigmentation upon Wood's lamp darkroom examination, consistent with a primarily epidermal melasma location. Grounds for exclusion included pregnancy, use of retinoids or other prescription anti-aging or skin lightening products over the previous four weeks, having received cosmetic clinical procedures in the last six months and pre-existing skin diseases that would impair the successful completion of the clinical study. Prospective participants were also deemed ineligible if diagnosed with dermal melasma upon Wood's lamp examination.



**FIGURE 1.** Melasma improvement scoring, with respect to baseline, was conducted at 12 and 16 weeks by all volunteers (N=5) and two blinded physician assessors. Blinded volunteer **a)** and physician **b)** & **c)** assessments demonstrate that twice daily oligopeptide treatment is significantly (\*\* $P < 0.001$ ) more effective at improving melasma than placebo.

All participants signed written consent documents prior to participation in the study and were required to be available for longitudinal study over the course of at least four months in order to assure appropriate follow-up. Digital photography was taken at baseline, 8, 12 and 16 weeks following treatment initiation. Two physicians graded improvement in the appearance of melasma in a blinded manner using a 10-point scale (each point equal to a 10% improvement).

Two physicians graded improvement in the appearance of melasma by comparing 12- and 16-week photos to baseline photos. Participants were asked to rate their improvement based on their own perception without the aid of any photographs. At 16 weeks, participants and both physicians additionally graded overall facial appearance in a blinded manner using a four-point global assessment scale (0 = no improvement, 1=1–25% improvement, 2=26–50% improvement, 3=51–75% improvement, 4=76–100% improvement). Physicians used digital photos taken at baseline and 16 weeks to evaluate improvement in overall appearance while participants graded their appearance based on perception alone.

Study participants also rated their satisfaction, in a blinded manner, with the visual improvement, or lack thereof, they obtained on either side of their face at 16 weeks using a four-point scale (0 = not satisfied, 1 = mildly satisfied, 2 = moderately satisfied, 3 = very satisfied and 4 = extremely satisfied).

All statistical data is presented as mean ( $\pm$  SD). Statistical significance (two-tailed) for melasma improvement scores and global assessments was determined using two-way ANOVA with a Bonferroni post-test. Statistical significance (two-tailed) for satisfaction scores was determined using a t-test. All evaluations were performed using the Prism 5 (Graphpad Software, Inc., La Jolla, CA) statistical software suite.

## RESULTS

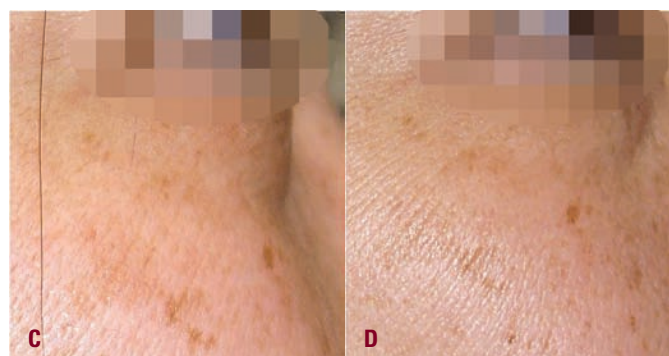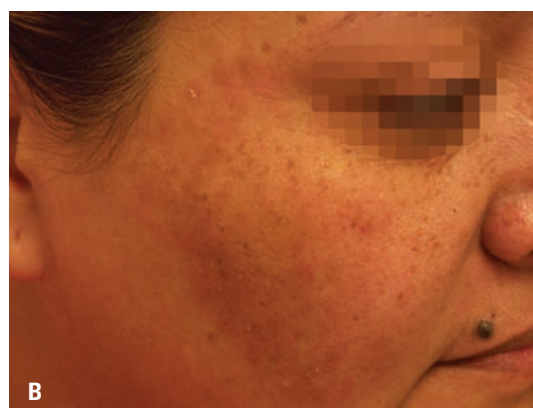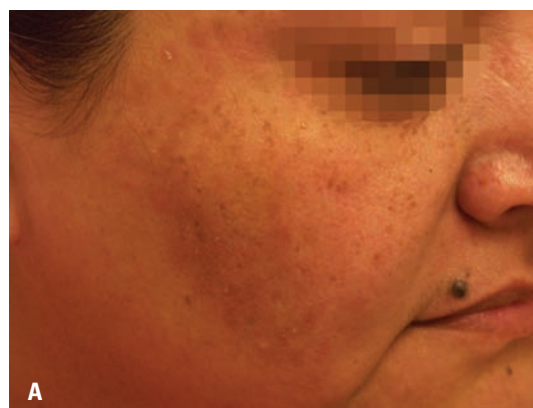Five healthy women between the ages of 32 and 42 (mean age  $36.8 \pm 3.7$ ) were enrolled in and completed the study. Three of the volunteers were of Hispanic decent and two were of Asian decent. All five participants had Fitzpatrick type IV skin types and presented with moderate recalcitrant melasma. Upon Wood's light examination, all five subjects demonstrat-

ed facial pigment accentuation, consistent with a diagnosis of epidermal rather than dermal melasma. Medical histories demonstrated that all participants previously failed to show improvement in melasma after six months of treatment with Tri-Luma. All patients subsequently were discontinued off Tri-Luma and completed a four-week wash out period prior to beginning treatment in the study.

The oligopeptide formula was well tolerated and participants showed no signs of irritation or allergic reaction. Melasma improvement scores from volunteers and physician graders were in agreement with each other showing >40% improvement at 12 weeks and >50% improvement at 16 weeks on the oligopeptide-treated side of the face (Figure 1). Improvement in melasma did not exceed 4% on the placebo side at any time-point as assessed by both participants and blinded physicians (Figure 1). By eight weeks, patients began reporting noticeable improvement in the oligopeptide-treated side (Figures 2C and D), with continued additional benefit at the 12- and 16-week time points. For the placebo side, participant and blinded physician evaluations of digital photography did not reveal any significant improvement in melasma at 16 weeks post-treatment compared to baseline (Figures 2A and 2B). Global assessment scores also demonstrated good agreement between participants and physician graders, showing >70% improvement in overall appearance of facial skin on the side treated with the oligopeptide formula (Figure 3). Global assessment scores for the placebo side demonstrated up to a 15% improvement in overall facial appearance. Moreover, volunteer satisfaction scores showed that two of five participants were very satisfied and three of five were extremely satisfied with their appearance on the oligopeptide-treated side (Figure 4). In contrast, two of five participants reported mild satisfaction and three of five said they were not satisfied with their appearance on the placebo-treated side.

## DISCUSSION

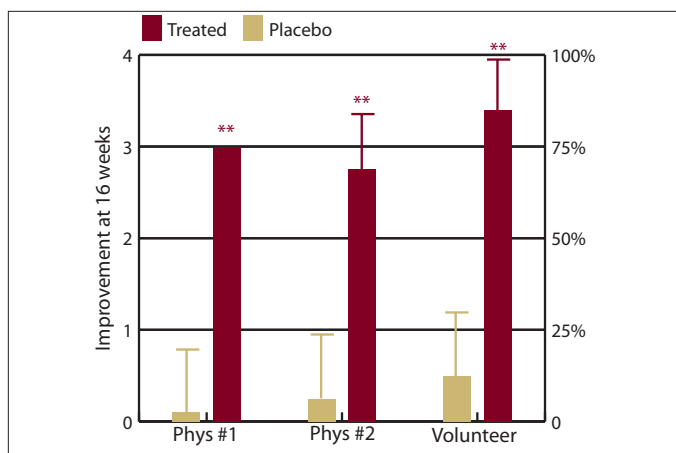
Previous results obtained in our laboratory indicated that the proprietary oligopeptide inhibited melanin production in normal human melanocyte cultures by competitive inhibition of tyrosinase without any cytotoxicity.<sup>6</sup> The present translational pilot clinical study provides further evidence that topical application of the oligopeptide may also inhibit melanogenesis in vivo with no apparent irritation to skin. Although the vehicle was not formulated for optimal transdermal delivery of the oligopeptide to the basal epidermis, the present results suggest that a sufficient concentration was able to penetrate the stratum corneum. This resulted in the observed improvement in the appearance of melasma, as placebo application during the same period led to virtually no change. Moreover, these results suggest that the oligopeptide may be effective for treating recalcitrant melasma in patients who failed treatment with Tri-Luma or the less efficacious hydroquinone alone.



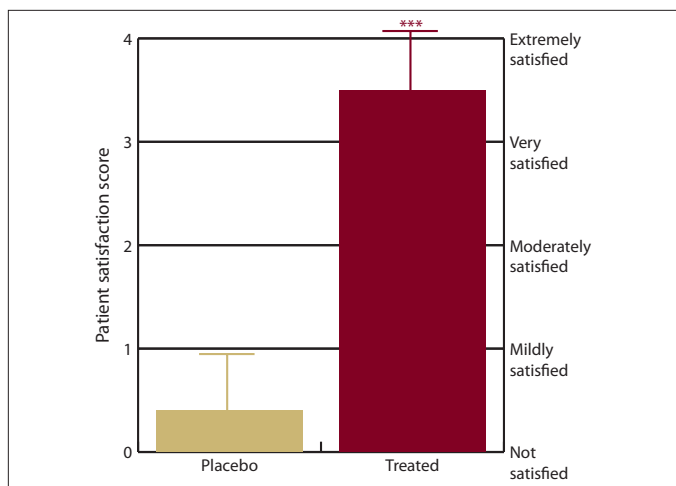
**FIGURE 2.** Subjects were placed on twice-daily topical application of placebo **a)** & **b)** or the oligopeptide-containing cream **c)** & **d)** and digital photography was taken at baseline **a)** & **c)**, **8 d)** or **16 b)** weeks. A mean score of 3 on a 10-point scale, or 30%, improvement in melasma was reported by subjects as early as 8 weeks post-treatment initiation. No improvement was detected by 16 weeks post-treatment initiation for the placebo side.

## CONCLUSION

The present results and high participant satisfaction suggest that the tested oligopeptide may be a safe and useful treatment for melasma that warrants further clinical evaluation.



**FIGURE 3.** Global assessment scoring was conducted at 16 weeks by the volunteers (n=5) and two blinded physician assessors to determine the overall improvement in facial appearance after using the oligopeptide and placebo treatments. Blinded volunteer and physician assessments indicate that twice daily oligopeptide treatment was significantly (\*\* $P < 0.001$ ) more effective at improving the overall appearance of facial skin than placebo.



**FIGURE 4.** Blinded volunteers (n=5) rated their satisfaction with the improvement in their facial melasma after 16 weeks. Data indicate that volunteers were significantly (\*\*\*) more satisfied with the improvements brought about by the oligopeptide treatment than that of the placebo.

## DISCLOSURES

Drs. Hantash and Jimenez have no relevant conflicts of interest to disclose.

## REFERENCES

1. Grimes PE. Diseases of hyperpigmentation. In: Sams WM, Lynch PJ, eds. *Principles and Practice of Dermatology*. New York: Churchill Livingstone; 1990:807-819.

2. Grimes PE. Melasma. Etiologic and therapeutic considerations. *Arch Dermatol*. 1995;131(12):1453-1457.
3. Ferrario E. Observations on cutaneous hyperchromia during pregnancy. *Riv Ostet Ginecol*. 1962;17:793-816.
4. Takase Y, Watanabe K. Endocrinological study of pigmentation disorders. *Horomon To Rinsho*. 1967;15(9):705-710.
5. Solano F, Briganti S, Picardo M, Ghanem G. Hypopigmenting agents: An updated review on biological, chemical and clinical aspects. *Pigment Cell Res*. 2006;19(6):550-571.
6. Abu Ubeid A, Zhao L, Wang Y, Hantash BM. Short-sequence oligopeptides with inhibitory activity against mushroom and human tyrosinase. *J Invest Dermatol*. 2009; In Press.

## ADDRESS FOR CORRESPONDENCE

### Basil M. Hantash, MD, PhD

Elixir Institute of Regenerative Medicine

5941 Optical Court

San Jose, CA 95138

Phone: ..... (323) 306-4330

Fax: ..... (323) 306-4330

E-mail: ..... basil@elixirinstitute.org